

Recurrent Dermatofibrosarcoma Protuberans: A Case Report

S.R. TELKAR, S.B. KUNTOJI, V.D. DOMBALE, H.B. KOTABAGI, B.A. KOLHAR

ABSTRACT

Dermatofibrosarcoma protuberans is an uncommon, locally aggressive, cutaneous, soft tissue sarcoma. It is most commonly seen on the trunk and it frequently recurs locally after an incomplete excision, but distant metastasis is rare. Patients

need post-operative local irradiation even with histopathological clear margins, following wide excision, owing to its high affinity for local recurrence. Here, we are reporting a case of recurrent dermatofibrosarcoma protuberans which was seen over the lower part of the abdomen.

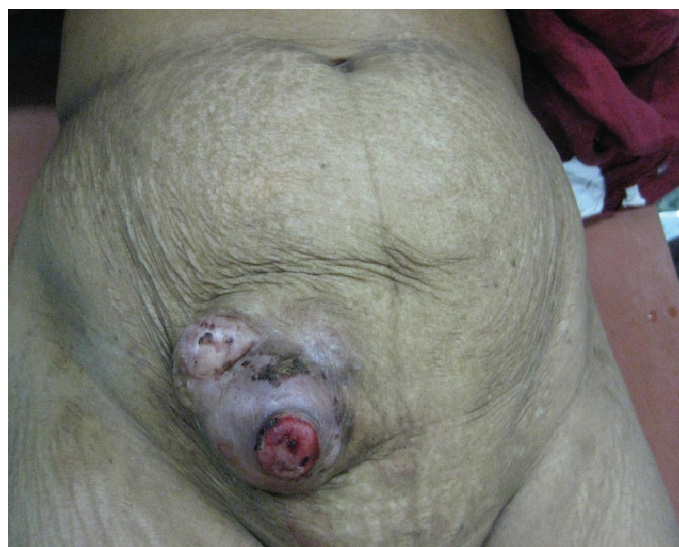Key Words: Dermatofibrosarcoma, Recurrent soft tissue tumour, Skin tumour

INTRODUCTION

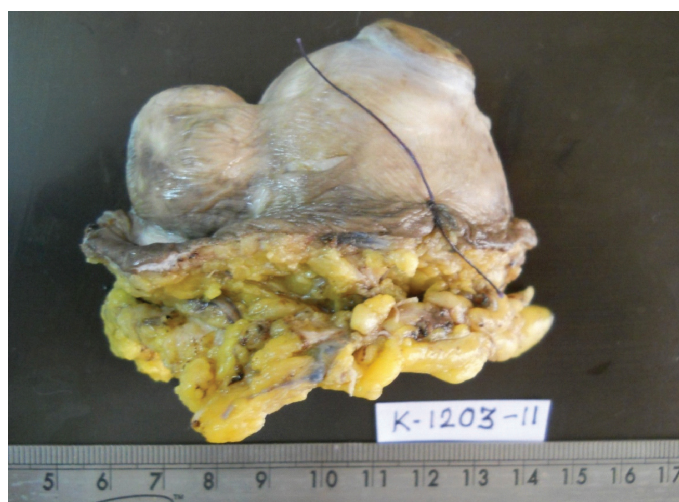
Dermatofibrosarcoma Protuberans (DFSP) is a low-grade, relatively uncommon, soft-tissue sarcoma that was originally described in 1924 by Dreier and Ferrand [1,2]. The term 'DFSP' was coined by Hoffman in 1925 [2]. It accounts for less than five percent of the soft-tissue tumours and 0.1 percent of all the malignancies, with an annual incidence of 0.8 to 4.5 per million. It is most commonly seen among those in the third or fourth decades of life and it favours the trunk (40-60%), followed by the proximal extremities (20-30%) and the head and neck (10%-16%) [3,4]. A slight male predominance has been reported among patients with DFSP [5]. It occurs less frequently in children, and congenital forms of dermatofibrosarcoma protuberans have been reported in the literature [6]. The tumour has low chances of metastasis, either to the regional lymph nodes or distantly, but it is aggressive locally. The biopsy typically shows the lesion to be located primarily in the dermis, with irregular infiltration of the subcutaneous fat in a lace-like pattern. The epidermis is usually spared, but it can be hyperplastic. The lesion usually comprises fairly uniform spindle cells with elongated nuclei and scanty pale cytoplasm. Pleomorphism is minimal or absent. The cells are typically arranged in a storiform or a mat-like pattern.

CASE REPORT

A 42-year-old female patient presented with a swelling in the right iliac quadrant of the abdomen [Table/Fig-1]. The patient was operated for the swelling at the same site two years back. The patient was symptom free for two years following her first surgery. Since one year, she noticed a swelling at the same site, which was increasing in size. As she was operated in a rural place, due to non-availability of histopathological facilities, the diagnosis was not proved. The examination revealed ulcerative right iliac swelling, approximately of a size of 20 × 15 cms, with bleeding and induration around. Pre-operatively, edge biopsy was done and the swelling was reported to be a spindle cell tumour. Sonography of the abdomen and chest X-ray and X-ray of the spine revealed no evidence of metastases. Wide excision was done under spinal anesthesia with a 3.5 cm clear margin and the tumour was freed from the rectus sheath. Primary closure of the wound was done after placing a suction drain. The post-operative period was uneventful and the patient

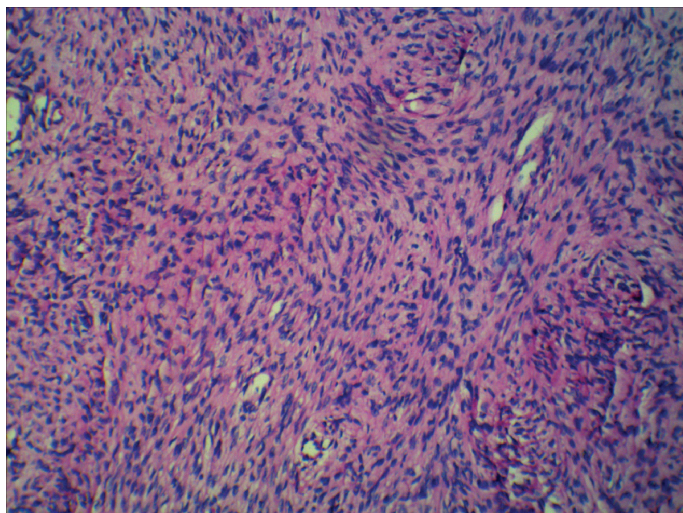


[Table/Fig-1]: Preoperative photograph showing the tumour



[Table/Fig-2]: Gross Histopathological picture showing the tumour

was discharged on the seventh day. The patient came for follow-up after one month. Her surgical wound had healed well and she was advised post-operative radiotherapy to prevent subsequent



[Table/Fig-3]: Microscopic picture showing the tumour

recurrence. Her histopathological examination showed DFSP with all the margins free of the tumour [Table/Fig-3].

DISCUSSION

Dermatofibrosarcoma protuberans is a relatively rare tumour, with only 0.8 to 4.5 cases per million persons per year having this tumour [7,8]. In the United states, dermatofibrosarcoma protuberans accounts for between 2 and 6 percent of all the soft tissue sarcomas [9,10] and 18 percent of all the cutaneous soft tissue sarcomas [8].

Surgical excision with 3 to 5-cm-wide margins was the recommended treatment, but it was associated with high rates of local recurrence. The extent of its invasion was difficult to ascertain because of its ability to penetrate not only the cutaneous and the sub-cutaneous tissues, but also the underlying fascia and muscles [5]. In a three-dimensional view, the tumour can be visualized to send projections in different directions and so, even a wide excision may leave behind residual tumour in single or multiple foci [11,12]. Radiotherapy has been used as an adjuvant therapy after wide surgical excision or in those patients who have inoperable macroscopic disease. Post-operative radiotherapy has been associated with a cure rate of 85 percent [13]. Ballo, et al, evaluated a combination of conservative resection and adjuvant radiation therapy and noted a local recurrence rate of 5 percent

[14]. The risks of adjuvant radiotherapy include acute and chronic radiodermatitis and further development of new skin cancers. The majority of local recurrences of dermatofibrosarcoma protuberans occur within the first three years, with about a half presenting within one year of surgery, but recurrences after five years have also been reported [11,15]. Thus, it is important to follow up these patients over a long period after the treatment. Here, we presented a rare case of recurrent DFSP after two years.

REFERENCES

- [1] Beech DJ, Long AB, Long WP. Dermatofibrosarcoma protuberans and breast cancer: genetic link or coincidental association? *Am Surg.* 2004; 70:543–45.
- [2] Hoffman E. Über das knollentreibende fibrosarkom de haut. *Dermatol Z.* 1925; 43:1–28.
- [3] Gloster HM. Dermatofibrosarcoma protuberans. *J Am Acad Dermatol.* 1996; 35:355–74.
- [4] Criscione VD, Weinstock MA. Descriptive epidemiology of Dermatofibrosarcoma protuberans in the United States, from 1973 to 2002. *J Am Acad Dermatol.* 2007; 56:968–73.
- [5] Asquo ME, Umoh MS, Ebughe G. Dermatofibrosarcoma protuberans: case reports. *Ann Afr Med.* 2007; 6: 80–83.
- [6] Reddy C, Hayward P, Thompson P, et al. Dermatofibrosarcoma protuberans in children. *J Plast Reconstr Aesthet Surg.* 2007; 18.
- [7] Gloster HM Jr. Dermatofibrosarcoma protuberans. *J Am Acad Dermatol* 1996; 35:355.
- [8] Rouhani P, Fletcher CD, Devesa SS, Toro JR. Cutaneous soft tissue sarcoma incidence patterns in the U.S: an analysis of 12,114 cases. *Cancer* 2008; 113: 616.
- [9] Chang CK, Jacob IA, Salti GI. Outcomes of the surgery for Dermatofibrosarcoma protuberans. *Eur J Surg Oncol* 2004; 30:341.
- [10] Kransdorf MJ. Malignant soft tissue tumors in a large referral population: distribution of diagnoses by age, sex, and location. *Am J Roentgeol* 1995; 164: 129.
- [11] Ratner D, Thomas CO, Johnson TM, et al. Moh's micrographic surgery for the treatment of Dermatofibrosarcoma protuberans. Results of a multi-institutional series with an analysis of the extent of microscopic spread. *J Am Acad Dermatol.* 1997; 37:600–13.
- [12] Haycox CL, Odland PB, Olbricht SM, et al. Dermatofibrosarcoma protuberans (DFSP): growth characteristics based on tumour modeling and a review of the cases which were treated with Moh's micrographic surgery. *Ann Plast Surg.* 1997; 38: 246–51.
- [13] Mendenhall WM, Zlotecki RA, Scarborough MT. Dermatofibrosarcoma protuberans. *Cancer.* 2004; 101: 2503–08.
- [14] Ballo MT, Zagars GK, Pisters P, et al. The role of radiation therapy in the management of Dermatofibrosarcoma protuberans. *Int J Radiat Oncol Biol Phys.* 1998; 40: 823–27.
- [15] Ruiz-Tovar J, Fernandez GM, Reguero CME, et al. Dermatofibrosarcoma protuberans: a review of a 20 year experience. *Clin Transl Oncol.* 2006; 8:606–10.

AUTHOR(S):

1. Dr. S.R. Telkar
2. Dr. S.B. Kuntoji
3. Dr. V.D. Dombale
4. Dr. H.B. Kotabagi
5. Dr. B.A. Kolhar

PARTICULARS OF CONTRIBUTORS:

1. Assistant Professor, Dept. of Surgery, SN Medical College and HSK Hospital, Bagalkot, Karnataka, India.
2. Professor, Dept. of Surgery, SN Medical College and HSK Hospital, Bagalkot, Karnataka, India.
3. Professor, Dept. of Pathology, SN Medical College and HSK Hospital, Bagalkot, Karnataka, India.
4. Professor, Dept. of Pathology, SN Medical College and HSK Hospital, Bagalkot, Karnataka, India.

5. Assistant Professor, Dept. of Surgery, SN Medical College and HSK Hospital, Bagalkot, Karnataka, India.

NAME, ADDRESS, TELEPHONE, E-MAIL ID OF THE CORRESPONDING AUTHOR:

Dr. S.R. Telkar
Assistant Professor, Dept. of Surgery,
SN Medical College and HSK Hospital,
Bagalkot, Karnataka, India - 587101.
Phone -918354-235400
E-mail: telkar76@gmail.com

DECLARATION ON COMPETING INTERESTS:

No competing Interests.

Date of Submission: Jul 04, 2011
Date of peer review: Sep 09, 2011
Date of acceptance: Nov 15, 2011
Date of Publishing: Dec 25, 2011